SonoPath
Clinical Sonography & Telecytology

EDUCATIONAL TELECONSULTATION SERVICES™

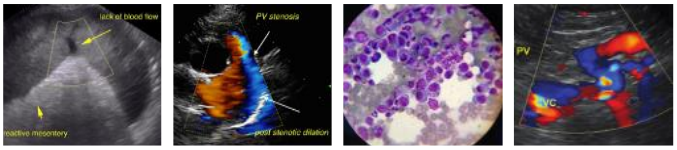

SonoPath.com™
1-800-838-4268 info@sonopath.com

PATIENT
Twixie Peters

SPECIES
Canine

BREED
Chihuahua Mix

SEX
Female Spayed

AGE
11 years

WEIGHT
7.8lbs

INTERPRETED BY
Maggie Machen Lamy, DVM, DACVIM (Cardiology)

IMAGING PERFORMED BY
Karen Ebersole, DVM, DABVP

HOSPITAL NAME
Scanvet

REFERRING VET
Dr. McGarvey

INVOICE
30139

DATE
4/10/23

PRESENTING CLINICAL SIGNS

History: History of heart disease and murmur. Weight loss and difficulty eating. Assess prior to anesthesia.
-Current medications: Pimobendan 1.25mg in am, 0.625mg in pm. Trazodone PO for sedation.

ECHOCARDIOGRAM FINDINGS

2D, m-mode, color flow and doppler imaging is available. Diffuse thickening of mitral valve leaflets (anterior>posterior) with prolapse into the left atrial lumen. Moderate eccentric mitral regurgitation with moderate left atrial dilation. Normal MR velocity. Mildly increased LV diameter with hyperdynamic myocardial function. The tricuspid valve appears subjectively normal, with mild tricuspid regurgitation. Normal velocity. Normal right atrial and ventricular diameter. The pulmonic and aortic valves are normal in morphology and mobility. Normal pulmonic and aortic outflow velocities. No aortic or pulmonic insufficiency. No pericardial or pleural effusion noted. No cardiac tumors observed. Arrhythmia noted.

CARDIAC CHART

CANINE CARDIAC PARAMETERS	MR VMAX (m/s)	TR VMAX (m/s)	LA/AO (Boon method)	LA/AO (Heart Base; Swe)	FS (%)	EF (%)	EPSS (cm)
NORMAL PARAMETER	4.5-5.5	<2.7	1.3	<1.6	28-40	40-100	<0.6
PATIENT	5.8	2.6	NM		.85	70	NM
CANINE CARDIAC PARAMETERS	**HR** (BPM)	**AV VMAX** (m/s)	**PV MAX** (m/s)	**BODY WEIGHT** (kg)	**LA** 2D short axis Base view (cm)	**LVIDd** Avg; 2D and m-mode short axis (cm)	**LVIDs** Avg; 2D and m-mode short axis (cm)
NORMAL PARAMETER	50-100	0.7-1.7	0.7-1.6	BELOW	BELOW	BELOW	BELOW
PATIENT	111	1.6	1.1	3.5	2.0	2.3	1.4
*Normal chamber parameters expressed as a mean value (SD)				3	1.27 (5.3)	2.46 (2.46)	1.36 (5.5)
BODY WEIGHT DEPENDENT PARAMETERS				5	1.40 (4.5)	2.74 (5.2)	1.60 (4.7)
**Note: All measurements based upon multi-modal images and methods. An average value is reported.*				10	1.50 (3.8)	3.27 (3.5)	2.06 (3.1)
				15	1.83 (2.0)	3.71 (2.4)	2.43 (2.1)
				20	2.02 (1.9)	4.14 (2.2)	2.80 (2.0)
Adapted from June Boon, Veterinary Echocardiography, 1998				25	2.18 (2.4)	4.48 (2.9)	3.10 (2.5)
Rishniw M and Hollis NE, J Vet Intern Med 2000; 14:429-435				30	2.33 (3.3)	4.83 (3.9)	3.39 (3.4)
Hansson et al, Vet Rad and Ultrasound 2002				35	2.48 (4.3)	5.17 (5.0)	3.69 (4.5)
Bonagura et al. Echocardiography: principles of interpretation, Vet Clin North Am 15:1177, 1995				40	2.62 (5.2)	5.48 (6.1)	3.96 (5.4)
				50	2.88 (7.1)	6.07 (8.3)	4.46 (7.4)

INTERPRETATION OF THE FINDINGS & FURTHER RECOMMENDATIONS

Chronic degenerative valve disease causing moderate mitral and mild tricuspid regurgitation. Moderate left atrial enlargement indicates there is relatively low risk for imminent complication, however risk for progression to spontaneous congestive heart failure in the future is elevated. No additional issues are identified. An intermittent arrhythmia is suspected, and a baseline ECG recommended.

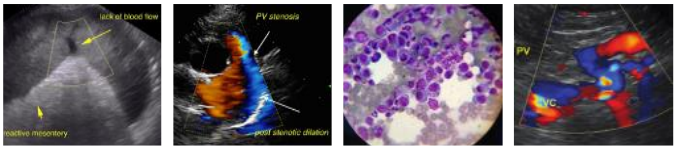

SonoPath.com
1-800-838-4268 info@sonopath.com

PATIENT
Twixie Peters

SPECIES
Canine

BREED
Chihuahua Mix

SEX
Female Spayed

AGE
11 years

WEIGHT
7.8lbs

INTERPRETED BY
Maggie Machen Lamy, DVM, DACVIM (Cardiology)

IMAGING PERFORMED BY
Karen Ebersole, DVM, DABVP

HOSPITAL NAME
Scanvet

REFERRING VET
Dr. McGarvey

INVOICE
30139

DATE
4/10/23

Given these findings, continued Pimobendan is indicated in this patient as below. Additionally, a baseline BP is recommended with institution of an ACE-I if warranted. Assessment of progression in the future will help predict long term outcome, however prognosis is guarded at this stage (B2). Omega fatty acid supplementation and mild salt restriction may also be of some long-term benefit. Monitor for development of a progressive cough, labored breathing, exercise intolerance or collapse episodes.

Anesthetic risk is considered mildly elevated. Cardiac protective drug choices (opioid/benzodiazepine premedication, Propofol or alfaxalone induction, iso or sevo gas) are recommended. Monitor for arrhythmias, hypotension, and hypoxia both intra and post-operatively and intervene as necessary. Judicious IV fluid rates are recommended to avoid fluid overload. Avoid heart rate stimulating drugs such as atropine unless clinically indicated.

PLAN

Continue Pimobendan 0.25-0.3mg/kg PO q12h. Baseline ECG and BP recommended. If BP>150mmHg, institute ACE-I 0.5mg/kg Po q12h.

Recommend monitor for progression with a recheck echocardiogram in 6 months, sooner if any development of clinical signs.

IMAGES

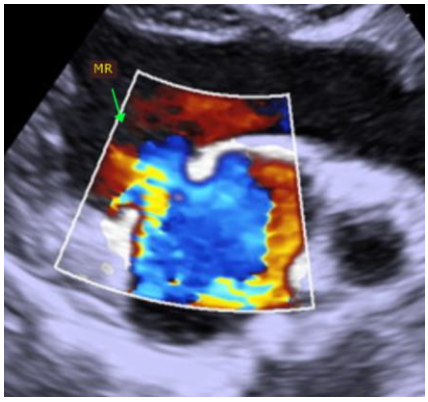

The information and recommendations provided are based on the images presented by the referring veterinarian. No evaluation can be communicated regarding pathology that was not visible in the image/video clips provided.

Thank you for this referral. This report was generated using transcription software, and minor dictation errors may be present. If the clinical or image interpretation does not parallel your findings or if I can be of any further assistance, please contact me.

Maggie Machen Lamy, DVM
Diplomate of the American College of Veterinary Internal Medicine (Cardiology)
info@sonopath.com

SonoPath
Clinical Sonography & Telecytology
EDUCATIONAL TELECONSULTATION SERVICES™

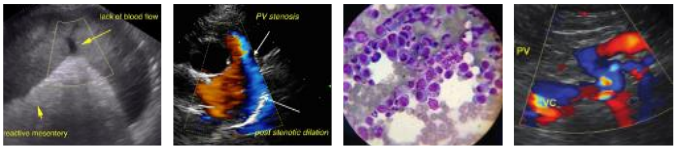

SonoPath.com™
1-800-838-4268 info@sonopath.com

PATIENT

Twixie Peters

SPECIES

Canine

BREED

Chihuahua Mix

SEX

Female Spayed

AGE

11 years

WEIGHT

7.8lbs

INTERPRETED BY

Maggie Machen Lamy, DVM, DACVIM (Cardiology)

IMAGING PERFORMED BY

Karen Ebersole, DVM, DABVP

HOSPITAL NAME

Scanvet

REFERRING VET

Dr. McGarvey

INVOICE

30139

DATE

4/10/23